

## A Case Report of a Sternal Plasmocytoma

Nada Adjou\*, Hatim Essaber, Fatma EL Mabrouk, Abdelilah El Barrichi, Jesse Omor, Rachida Latib, Sanae Amalik, Fouad Kettani

Radiology department of the national institute of Oncology of Rabat (INO), Morocco.

\*Corresponding author: Nada Adjou.

### Introduction

Our patient was 55 years old, with no particularly medical history, who consults in our training center

for a sternal swelling and a progressive chest pain. A thoracic injected CT-scan was performed (Figure 1 and 2).

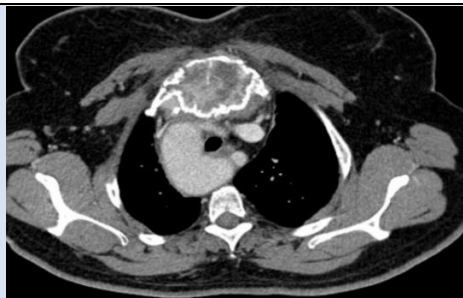

Figure 1: Axial section of an injected CT-scan, focused on the sternal mass

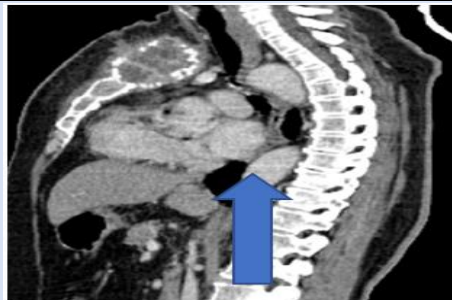

Figure 2: Sagittal cut of an injected CT-scan, focused on the sternal mass.

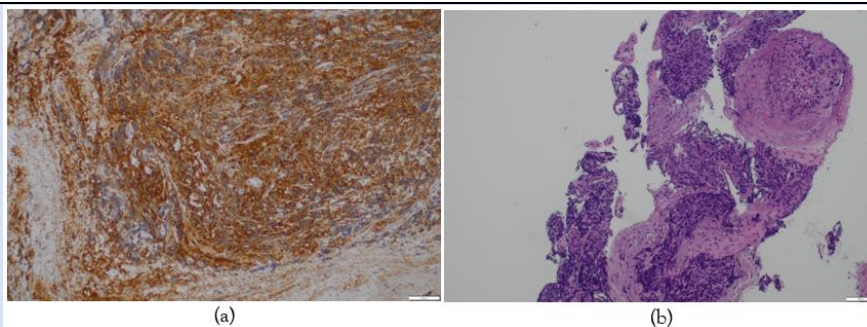


Figure 3: Anatomopathology results of the biopsy of the sternal mass (enlargement x500um (a) et x 100 (b))

Where we can see a sternal osteolytic mass (manubrial and corporal), rupturing the cortex with a multi-lamellar periosteal reaction. Extension to the soft tissue is clearly visible, with infiltration of the pectoralis major and minor and external intercostal muscles, and a heterogeneous, swollen appearance of the intentional fibers of the sternocleidomastoid

muscles. This mass also extends to the anterior mediastinal fat posteriorly (as seen in Figure 1).

### Discussion

Solitary plasmacytoma is a rare plasmacytic tumor [1]. It embraces two distinct entities related to tumor location / either bone (solitary plasmacytoma in bone) or soft tissue (solitary plasmacytoma extra

medullary) [2]. Solitary bone plasmacytoma is characterized by a single lesion most often affecting the axial skeleton, mainly the vertebrae [3]. The diagnosis is based on histological confirmation of plasma cell proliferation, absence of bone marrow dissemination, uniqueness of the lesion, and absence of anemia, hypercalcemia or renal involvement suggesting a diagnosis of diffuse myeloma [4-5]. Solitary bone plasmacytoma can affect all bones: the most common location is the dorsolumbar spine in 30 to 40% of the cases, and long bones are affected in 20 to 40% of the cases [3-7-11]. Sternal involvement remains rare. The CT-Scan shows a lytic lesion that takes up contrast intensely and homogeneously; it allows a better study of the local extension and look for possible infra-radiological bone localizations [6-11]. Due to the non-specificity of radiological images, the diagnosis is based on anatomopathological study of the surgical specimen or CT-guided trans parietal biopsies, showing sheet-like plasma cell proliferation with dysmorphic plasma cells with nuclear abnormalities and normal cytoplasm [8-9]. To discard the diagnosis of diffuse myeloma metastasis, a complete workup is required, including bone marrow biopsy, bone scan with skeletal X-Rays (especially of the spine, pelvis and skull) and serum and urine protein immunoelectrophoretic, which can reveal abnormal monoclonal protein secretion in half of solitary plasmacytomas [6-9-11]. Radiotherapy is the gold standard for the treatment of solitary plasmacytoma of the bone, either alone or in conjunction with surgery. It achieves a local control rate of over 90%, with excellent tolerability and rapid, long-lasting analgesic action [10]. The prognosis of PSO is mainly favorable, with an average survival of over ten years [11], but the risk of progression to multiple myeloma is estimated at 31 to 75 % depending on the studies, which justifies regular monitoring and follow-up of affected patients [3].

## Conclusion

Although rare, solitary sternal plasmacytoma should be considered in the presence of any lytic sternal mass. Treatment is essentially based on radiotherapy with or

without surgery. Its prognosis is conditioned by progression to multiple myeloma, which justifies rigorous and regular monitoring.

## References

1. Knowling MA, Harwood AR, Bergsagel DE. (1983). Comparison of extramedullary plasmacytomas with solitary and multiple plasma cell tumors of bone. *J Clin Oncol*, 1:255-26.
2. Galieni P, Cavo M, Avvisati G et al. (1995). Solitary plasmacytoma of bone and extramedullary plasmacytoma: two different entities? *Ann Oncol*, 6:687-691.
3. Kochbati L, Kédidi Ben Romdhane N, Mrad K, Nasr C, et al. (2004). Solitary bone plasmacytoma: therapeutic and evolutionary aspects. *Cancer/Radiotherapy*, 8(2):70-74.
4. Dimopoulos MA, Moullopoulos LA, Maniatis A, Alexanian R. (2000). Solitary plasmacytoma of bone and asymptomatic multiple myeloma., 96:2037-2044.
5. Bousnina S, Zendah I, Marniche K, Yalaoui S, El Mezni F, Meghdiche ML, et al. (2006). Solitary plasmacytoma with costal location: a rare tumor that should not be ignored. *Rev Pneumol Cli*, 62:243-246.
6. Kadokura M, Tanio N, Nonaka M, Yamamoto S, Kataoka D, Kushima M, et al. (2000). A surgical case of solitary plasmacytoma of rib origin with biclonal gammopathy. *Jpn J Clin Oncol*, 30:191-195.
7. El Abdi B, Arkha Y, Jroundi L, Mouhsine A, Chami I, Boujida N, et al. (2006). Quel est votre diagnostic ? *J Radiol*, 87:981-983.
8. Étienne G, Grenouillet M, Ghiringhelli C, Vatan R, Lazaro E, Germain P, et al. (2004). Pulmonary plasmacytoma: about two new observations and literature review. *Rev Med Intern*, 25:591-595.
9. Bencheikh R, Benhammou A, Rabeh G, Benbouzid MA, Boulaich M, Essakali L, et al. (2007). Plasmacytoma solitaire osseux de la mandibule. *Rev Stomatol Chir Maxillofac*, 108:135-138.
10. Tong D, Griffin TW, Laramore GE, Kurtz JM, Russell AH, Groudine MT, et al. (1980). Solitary plasmacytoma of bone and soft tissue., 135:195-198.
11. Sato Y, Hara M, Ogino H, Kaji M, Yamakawa Y, Wakita A, et al. (2001). CT-pathologic correlation in a case of solitary plasmacytoma of the rib. *Radiat Med*, 19:303-305.

**Cite this article:** Adjou N, Essaber H, Mabrouk F.E, Barrichi A.E, Omor Y, et al. (2024). A Case Report of a Sternal Plasmacytoma. *Journal of Radiology Research & Imaging*, BioRes Scientia Publishers. 1(1):1-2. DOI: 10.59657/jrri.brs.24.004

**Copyright:** © 2024 Nada Adjou, this is an open-access article distributed under the terms of the Creative Commons Attribution License, which permits unrestricted use, distribution, and reproduction in any medium, provided the original author and source are credited.

**Article History:** Received: May 21, 2024 | Accepted: June 12, 2024 | Published: June 19, 2024