

A Rare Case of Transverse Myelitis During Pregnancy, In A 23-Year-Old Female in A Resource-Limited Setup

Fatma S. Moh'd¹, Magreth Magambo², Richard kiritta², Amina yussuf², Fridolin Mujuni², Dismas Matovelo², Edgar Ndaboine², Elieza chibwe^{2*}

¹Department of Obstetrics and Gynecology, Bugando Medical Centre, Catholic University of Health and Allied Sciences, Mwanza, Tanzania.

²Department of Radiology, Bugando Medical Centre, Catholic University of Health and Allied Sciences, Mwanza, Tanzania.

*Corresponding author: Elieza chibwe.

Abstract

Background: Transverse myelitis (TM) is a rare, acquired neuro-immune spinal cord disorder that can present with the rapid onset of weakness, sensory alterations, and bowel or bladder dysfunction.

Case presentation: We report a case of 23-year-old woman, gravid two, para zero with one previous abortion, at a gestation age of 38 weeks and five days presented to the obstetric emergency of our hospital with complaints of neck pain for two days and weakness of upper limb and lower limb and inability to walk for one day with no history of trauma. She was delivered by emergency cesarean section due to fetal bradycardia (fetal heart tone ranging from 107 to 115 beats per minute) which was confirmed by a cardiotopographic machine. The caesarian section went well, where the alive baby girl with Apgar scores of six and ten in one and five minutes respectively, and her birth weight of 3.4 kilograms (kg) followed by postoperative order with the uncomplicated postpartum period. During treatment, magnetic resonance imaging (MRI) of the spine was done and a diagnosis of TM was made. She was managed with parenteral steroids and physiotherapy. She was later discharged from our hospital in good health plus an uneventful postnatal follow-up. We present this case as a rare diagnosis to our facility with successful management during pregnancy and the possibility of recovery in a resource-limited setup.

Conclusion: Transverse myelitis (TM) is a rare phenomenon in pregnancy, therefore obstetric care is needed, and if untreated in this critical condition, it may lead to complications such as deep vein thrombosis, urinary tract infections, and preterm labor. This will require an additional component of coordination between women and their families.

Keywords: transverse myelitis (TM); pregnancy; resource-limited setup

Introduction

TM is a rare inflammatory neurological disorder of the spinal cord that damages the myelin covering the spinal cord and affect the sensory, motor, and autonomic system. The prevalence of TM ranged from 0.4 to 1.5 per thousand deliveries worldwide [1]. The clinical features and diagnostic work-up have differed between different forms of TM in obstetrics.

Case presentation

A 23-year-old woman, gravid two, para zero with one previous abortion, her last normal menstrual period was the third of September 2020 and the expected date of delivery was the tenth of June 2021. Presented at Bugando Medical Centre (BMC) with a gestation age of 38 weeks and five days, and complaints of neck

pain for two days and weakness of upper and lower limbs for one day with no history of trauma. She was unable to sit without support, it was associated with lower limb pain, lack of sensation, and numbness. Also report a history of a headache but no fever, dizziness, blurred vision, or convulsion. The patient reports a history of increased urinary urgency, bowel incontinence, constipation, and sexual dysfunction. During admission, the patient was stable, weighed 67kg, and had a height of 168 centimeters, leading to a body mass index (BMI) of 23.74kg/m². Her hemodynamics were unstable with blood pressure (BP) of 154/96 mmHg, a temperature of 36.4° Celsius, a respiratory rate of 20 cycles/minute, and a pulse rate was 110beats/minute she was saturated 98% on room air.

Routine blood investigation showed hemoglobin of 8.8gm/ dl, red distribution width 19.5%, platelet count $202 \times 10^3/\text{mm}^3$ and neutrophils $7 \times 10^9/\text{l}$. Urine for a protein of +1, with normal urea, creatinine, and serum electrolytes. On abdominal examination, show a gravid uterus, with a fundal height was 36cm, a fetal heart rate was 105beats per minute, conformed by bedside ultrasound, with three contractions lasting for 30 seconds, with a longitudinal lie, a cephalic presentation where cervical dilated seven centimeters, fully effaced, head station-1, caput +2, no molding, with the adequate pelvis. Neurology consultation was obtained where muscle power was 4/5 in both upper limbs and 2/5 in both lower limbs, the bulk of both limbs was normal, while the tone was decreased in both limbs, pin, and light sensation decreased and she had abnormal gaits. All other neurological examinations were normal, including higher mental function, and

cerebellar. Based on the above findings, a contrast-enhanced MRI was advised after delivery. Because of fetal bradycardia, an emergency cesarean section was done, and extracted baby girl with Apgar scores of six and ten in one and five minutes respectively, birth weight of 3.4kilograms, placenta, and product of conceptus were fully removed, hemostasis was achieved, and the surgical wound closed by layer and followed by postoperative order of Injection pethidine, iv fluid, methyldopa and one unit of blood transfusion.

The patient was taken to a recovery room, and after two hours she was taken to the postnatal ward, high dependence unit for observation where ambulation and oral sips were then started. On the second day after the operation, an MRI of the spine was done (figure 1 and 2).

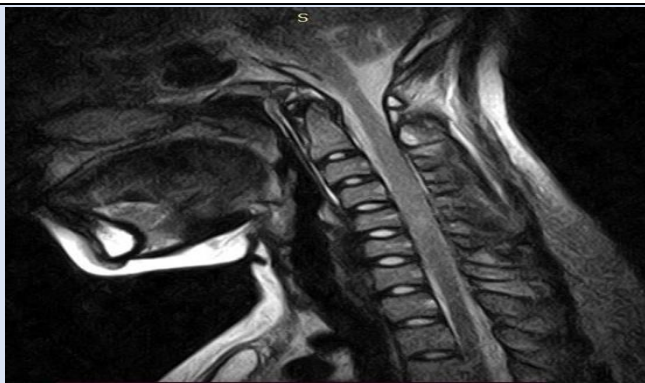

Figure 1: T2W images show segmental cervical cord thickening, a heterogeneous signal, with no focal mass formation within the spinal cord. There is mild, segmental thickening of the cervical cord over a length of three centimeters, from c3/4 to c4/5.

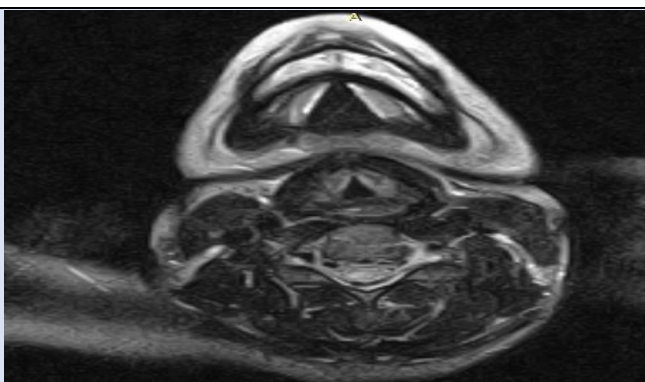


Figure 2: T2* axial images demonstrating the spinal cord focal high signal lesion which was low on T1w images.

She was started on an injection of methyl-prednisolone 1 gram intramuscular that was planned for five days and neuro-tone one tablet per oral once a day for one month. On successful management, blood pressure ranged from 128/80 to 135/85mmHg, hemoglobin 10gm/dl, power of upper limb become

5/5, power of lower limb was 4/5, normal tone on upper limb, pin, and light sensation become normal and gaits were improved but no improvement on urine retention. Hence patient was discharged on prednisolone 60mg per oral once a day for three days, then 50mg once a day for three days, then 40mg per

oral once a day for three days, then 30mg per oral once a day for three days. Omeprazole 40mg per oral once a day for two weeks, iron supplements, and discharged to a physiotherapy clinic. On the 14th-day patient come for a follow-up and show signs of improvement where the tone of the upper and lower limbs was 5/5 with a normal gait, and the catheter was removed with a good prognosis.

Discussion

Acute transverse myelitis (TM) is rare, during pregnancy [2], with a prevalence of 0.4 to 1.5 per 1000, and reported incidence is between one to eight new cases per million people per year, but is probably underestimated [3]. Concerning higher-income countries like the USA approximately 1400 new cases per year occur and about 34,000 people have chronic morbidity from TM. But due to the limited data in lower resource countries, no cases were reported in our setup, especially in our hospital.

This acquired heterogeneous pathological syndrome of neuro-immune spinal cord disorder that can present with the rapid onset of weakness, sensory alterations, and bowel or bladder dysfunction [1], have bimodal peak distribution of ages between 10 to 19 years and 30 to 39 years [4]. In many patients, the etiology is idiopathic, but in others, the main cause is post-infection paraneoplastic, drug-induced, autoimmune, and underlying demyelinating diseases. The symptoms started a day to weeks and keep worsening beyond one month, but presentation and prognosis vary between individuals [5]. In 30 to 60 percent of idiopathic TM cases, there is an antecedent respiratory, gastrointestinal, or systemic illness [4].

Subtypes of TM can be either acute partial TM refers to spinal cord dysfunction that is mild or grossly asymmetric with an MRI lesion extending one to two vertebral segments. Acute complete TM refers to spinal cord dysfunction that causes symmetric, complete or near-complete neurologic deficits (paresis, sensory loss, and autonomic dysfunction) below the level of the lesion with a magnetic resonance imaging (MRI) lesion extending one to two vertebral segments. Longitudinally extensive transverse myelitis (LETM) refers to complete or incomplete spinal cord dysfunction with a lesion on MRI that extends three or more vertebral segments [6].

The onset of TM is characterized by motor symptoms like paraparesis, and flaccidity and followed by spasticity. Sensory symptoms include pain, dysesthesia,

and paresthesia. Autonomic symptoms involve increased urinary urgency, bladder and bowel incontinence, difficulty or inability to void, constipation, and sexual dysfunction. Concerning our case patient presented with initial flaccid paralysis, followed by symptoms of pain, numbness, and urinary bladder symptoms with an inability of sexual intercourse. This is supported by data for over 470 individuals with idiopathic TM, the most common first symptoms were sensory change at 39%, weakness at 25%, and pain at 22% [7].

TM does not affect the ability of a woman to conceive and women affected with TM have the same chance of conception and likewise have the same risk of having a miscarriage before 20 weeks. The diagnosis of TM is suspected when there are acute or sub-acute signs and symptoms and localization of one or more contiguous spinal cord segments in patients with no evidence of a compressive cord lesion.

Where diagnosis criteria of TM for research purposes are sensory, motor, or autonomic dysfunction attributable to the spinal cord, MRI of the spinal cord in patients with TM typically shows a gadolinium-enhancing signal abnormality, usually extending over one or more cord segments and the cord often appears swollen at the affected levels of T2, no evidence of compressive cord lesion, bilateral signs and/or symptoms, clearly defined sensory level, we perform lumbar puncture where approximately one-half of patients have a moderate lymphocytosis (typically <100/microL), an elevated protein level (usually 100 to 120 mg/dL), normal glucose levels and elevated immunoglobulin G (IgG) in CSF, progression of the disease to nadir between 4 hours and 21 days [8]. As regards our case patient full fill in those criteria with exception of elevated immunoglobulin G in CSF. However, some patients presenting with TM may not fulfill all of the above criteria. As an example, a significant percentage of individuals with a clinical pattern that otherwise resembles TM does not meet the inflammatory features, therefore, the absence of inflammatory markers does not rule out TM [9].

Successful pregnancies with term vaginal deliveries can occur in preexisting TM but more attention should be given to the prevention of potential complications such as anemia, preterm labor and delivery, decubitus ulcers, and autonomic dysreflexia, this is achieved by coordinated multidisciplinary management [10]. Concerning our case, the patient enhanced on ambulatory although with difficulty by

dragging her feet, use of skin care, and was well educated on frequent position changing and wheelchair exercises to prevent upcoming complications.

Apart from that, autonomic dysreflexia is the most complication of TM in gravid patients, it is caused by a loss of descending control over sympathetic spinal reflexes which causes vasoconstriction, intracranial hemorrhage, and even death. Hypertension occurs in approximately 85% of pregnant women with spinal cord lesions at or above the sixth thoracic vertebra, symptoms do not usually occur until 72 hours after cord injury [11]. In our case patient presented with higher blood pressure and was managed with antihypertensive and returned to normotensive after one month.

On the part of the treatment of acute idiopathic TM, clinical judgment and radiological parameters must be regarded either use of a high-dose of intravenous glucocorticoid as soon as possible, unless there are relatively few contraindications and preferred regimens are methylprednisolone or dexamethasone for three to five day, as our case patient was kept on methylprednisolone on the third day of her illness [12]. Plasma exchange may also be effective for those that fail to respond to high-dose glucocorticoid treatment, which is not available in a lower-resource country like ours [13]. Also, there is a role of albumin instead of plasma, but fibrinogen levels should be monitored which was difficult in our setup [14]. For those presented with recurrent idiopathic TM, chronic immunomodulatory like mycophenolate and rituximab are the best options [15].

Most patients with idiopathic TM have at least a partial recovery, which usually begins within one to three months or can proceed over years, and continues with exercise and rehabilitation therapy. Some degree of persistent disability is common and can occur by 40 percent, a very rapid onset with complete paraplegia and spinal shock has been associated with poorer outcomes [16]. Concerning our case, complete recovery takes four months, during which our patient can stand without support and can control urine and feces.

The majority of patients with TM experience monophasic disease but recurrence also has been reported in approximately 25 to 33 percent of patients with idiopathic TM. With disease associated with TM, the recurrence rate may be as high as 70 percent, hence those who experience recurrence should be evaluated extensively to exclude rheumatological disorder,

systemic lupus erythematosus, and sarcoidosis [17]. Patients presenting with acute complete transverse myelitis have a risk to develop multiple sclerosis of only five to ten percent, the transition rate to multiple sclerosis over three to five years is 60 to 90 percent. In contrast, patients with acute partial myelitis who have a normal brain MRI develop multiple sclerosis at a rate of only 10 to 30 percent over a similar period [18].

Conclusion

TM is a critical and complicated case in obstetric scope where careful evaluation by obstetricians and neurologists can help to identify potential challenges and how best to manage them.

Patient's perspective

The care provided was timely with a full explanation of the diagnosis and prognosis and a follow-up plan explained.

Acknowledgments

We are humbly grateful for the support and encouragement were given by the Obstetrics/gynecology, and Radiology departments at Bugando Medical Centre and the Catholic University of Health & Allied Sciences (CUHAS).

Timeline: The patient was admitted on 31/5/2021 and management was initiated immediately. The intervention was done after birth, and the patient was admitted for a total of one month. Preparation and completion of the case took four months, including follow-up, and the case was presented to the ethical committee after obtaining consent.

Author's Contribution: co-authors contributed to the management of the patient and the writing of the case report. All authors read and approved the final manuscript.

Funding: The cost of preparing this manuscript will be covered by Catholic University of Health and Allied Sciences, Mwanza, Tanzania, P.O. Box 1464, Mwanza, Tanzania.

Ethical approval and consent to participate: Written informed consent was obtained from the Patient for publication of this case report, and ethical clearance was granted by the joint Catholic.

University of Health and Allied Sciences/ Bugando Medical Centre Research and Ethical review committee.

Consent for publication: Written informed consent was obtained from the patient for publication of this case and any accompanying images. A copy of the written consent is available for review by the Editor-in-Chief of this journal. Additionally, consent was sought and granted by the Catholic University of Health and Allied Sciences Directorate of Research and Publication to publish this work. A copy of the clearance document is also available for review by the Editor-in-Chief of this journal.

Competing interests: The authors declare that they have no competing interests.

References

1. Albert T, Ravaud J. (2005). Rehabilitation of spinal cord injury in France: a nationwide multicentre study of incidence and regional disparities. *Spinal cord*, 43(6):357-365.
2. Castro JS, Lourenço C, Carrilho M. (2014). Successful pregnancy in a woman with paraplegia. *Case Reports*, bcr2013202479.
3. Berman M, Feldman S, Alter M, Zilber N, Kahana E. (1981). Acute transverse myelitis: incidence and etiologic considerations. *Neurology*, 31(8):966.
4. Jeffery DR, Mandler RN, Davis LE. (1993). Transverse myelitis: retrospective analysis of 33 cases, with differentiation of cases associated with multiple sclerosis and parainfectious events. *Archives of neurology*, 50(5):532-535.
5. Krishnan C, Kaplin AI, Pardo CA, Kerr DA, Keswani SC. (2006). Demyelinating disorders: update on transverse myelitis. *Current neurology and neuroscience reports*, 6(3):236-243.
6. Beh SC, Greenberg BM, Frohman T, Frohman EM. (2013). Transverse myelitis. *Neurologic clinics*, 31(1):79-138.
7. Greenberg BM, Krishnan C, Harder L. New onset transverse myelitis diagnostic accuracy and patient experiences. *Multiple Sclerosis and Related Disorders*, 30:42-44.
8. Group* TMCW. (2002). Proposed diagnostic criteria and nosology of acute transverse myelitis. *Neurology*, 59(4):499-505.
9. De Seze J, Lanctin C, Lebrun C, Malikova I, Papeix C, et al. (2005). Idiopathic acute transverse myelitis: application of the recent diagnostic criteria. *Neurology*, 65(12):1950-1953.
10. Berghella V, Spector T, Trauffer P, Johnson A. (1996). Pregnancy in patients with preexisting transverse myelitis. *Obstetrics & Gynecology*, 87(5):809-812.
11. Verduyn W. Spinal cord injured women, pregnancy and delivery. *Spinal Cord*, 24(4):231-240.
12. Scott T, Frohman E, De Seze J, Gronseth G, Weinshenker B. (2011). Evidence-based guideline: clinical evaluation and treatment of transverse myelitis: report of the Therapeutics and Technology Assessment Subcommittee of the American Academy of Neurology. *Neurology*.
13. Nakanishi T, Suzuki N, Kuragano T, Nagasawa Y, Hasuike Y. (2014). Current topics in therapeutic plasmapheresis. *Clinical and experimental nephrology*, 18(1):41-49.
14. Greenberg B, Thomas K, Krishnan C, Kaplin A, Calabresi P, Kerr D. (2007). Idiopathic transverse myelitis: corticosteroids, plasma exchange, or cyclophosphamide. *Neurology*, 68(19):1614-1617.
15. Kaplin AI, Krishnan C, Deshpande DM, Pardo CA, Kerr DA. (2005). Diagnosis and management of acute myelopathies. *The neurologist*, 11(1):2-18.
16. Defresne P, Hollenberg H, Husson B, Tabarki B, Landrieu P, Huault G, et al. (2003). Acute transverse myelitis in children: clinical course and prognostic factors. *Journal of child neurology*, 18(6):401-406.
17. Brinar VV, Habek M, Brinar M, Malojcic B, Boban M. The differential diagnosis of acute transverse myelitis. *Clinical neurology and neurosurgery*, 108(3):278-283.
18. Bruna J, Martínez-Yélamos S, Martínez-Yélamos A, Rubio F, Arbizu T. (2006). Idiopathic acute transverse myelitis: a clinical study and prognostic markers in 45 cases. *Multiple Sclerosis Journal*, 12(2):169-173.

Cite this article: Fatma S. Mohmmad, Magambo M., kiritta R., Yussuf A., Chibwe E. et al. (2023). A Rare Case of Transverse Myelitis During Pregnancy, In A 23-Year-Old Female in A Resource-Limited Setup. *Clinical Case Reports and Studies*, BioRes Scientia Publishers. 3(1):1-5. DOI: 10.59657/2837-2565.brs.23.059

Copyright: © 2023 Elieza chibwe, this is an open-access article distributed under the terms of the Creative Commons Attribution License, which permits unrestricted use, distribution, and reproduction in any medium, provided the original author and source are credited.

Article History: Received: July 27, 2023 | Accepted: August 11, 2023 | Published: August 17, 2023